

# Interim Results of the PROMISE I Trial to Investigate the LimFlow System of Percutaneous Deep Vein Arterialization for the Treatment of Critical Limb Ischemia

J.A. Mustapha, MD<sup>1</sup>; Fadi A. Saab, MD<sup>1</sup>; Daniel Clair, MD<sup>2</sup>; Peter Schneider, MD<sup>3</sup>

**ABSTRACT: Objective.** To investigate the feasibility, safety, and effectiveness of the LimFlow stent-graft system in performing percutaneous deep vein arterialization (pDVA) for treatment of critical limb ischemia (CLI) patients ineligible for conventional endovascular or surgical revascularization procedures. **Methods.** Ten no-option CLI patients (mean age, 67 ± 11 years; 30% women) were enrolled. All patients were classified as Rutherford class 5 or 6 and were deemed by a committee of experts to be ineligible for endovascular or surgical procedures to restore blood flow. Eighty percent were categorized as stage 4 [high risk of amputation] based on Society for Vascular Surgery wound, ischemia, and foot infection [SVS WifI] scoring index. The primary safety endpoint was amputation-free survival [AFS] at 30 days. A secondary safety endpoint evaluated AFS at 6 months. Other secondary endpoints included primary patency, wound healing, and technical success. **Results.** Amputation-free survival was achieved in 100% of patients, with no deaths or index limb above-ankle amputations observed at 30 days and 6 months. Technical success rate was 100%. No procedural complications were reported. Primary patency rates at 1 month and 6 months were 90% and 40%, respectively, with reintervention performed in 30% of patients. By 6 months, 30% of patients experienced complete [100%] wound healing, half of patients had 84%-93% wound healing, and 20% of patients experienced 60% healing. **Conclusion.** pDVA using the LimFlow system is a novel approach for treating patients with no-option CLI and may reduce amputation in this population for whom it would otherwise be considered inevitable. Initial findings from this early feasibility trial are promising and additional study is warranted.

J INVASIVE CARDIOL 2019;31(3):57-63.

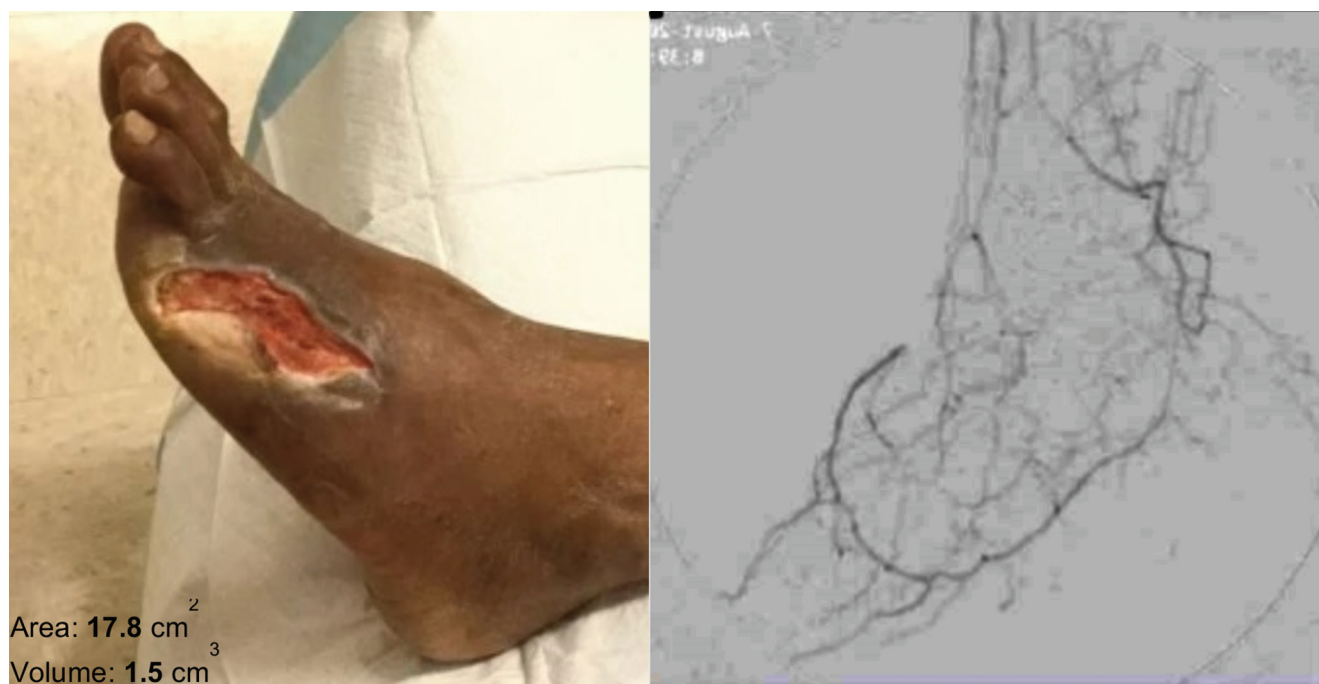**KEY WORDS:** critical limb ischemia, desert foot, stent-graft

Critical limb ischemia (CLI) represents the most advanced form of peripheral arterial disease (PAD). Its presentation is characterized by ischemic rest pain, non-healing ulceration, and/or gangrene (Rutherford categories 4 to 6), attributable to arterial occlusive disease.<sup>1</sup> Patients with CLI are heterogeneously complex and frequently endure chronic comorbidities including hypertension, hyperlipidemia, diabetes mellitus, and renal failure.<sup>2</sup> There is a broad spectrum of disease severity and, even with the diversity of contemporary treatment modalities, the therapeutic options for CLI patients are often limited. End-stage CLI pathology results in the occlusion of pedal arteries (desert foot), eliminating suitable targets for distal bypass. This advanced and complex disease also commonly results in failure of conventional revascularization treatment.<sup>3</sup> Even with aggressive local wound care, patients with severe limb ischemia and chronic ulceration who do not, or cannot, undergo revascularization frequently progress to amputation.<sup>4</sup> Up to 20% of CLI patients can face “no-option” situations, eg, due to the complexity or location of atherosclerotic lesions, lack of adequate conduit, or extensive co-morbidities, currently available surgical and endovascular techniques are not sufficient and major limb

amputation is considered as the only viable solution.<sup>5</sup> With increasing rates of diabetes and renal failure as well as increasing lifespans, this difficult population of no-option patients may continue to grow, increasing the need for an alternative option for limb salvage.<sup>6</sup>

Increased attention has been focused upon the quality of life (QoL) of CLI patients. A previous study that focused on CLI patients' QoL found that the subset of patients who had no surgical or endovascular treatment option reported inferior overall quality of life when compared to patients with milder forms of PAD, with physical functioning and bodily pain most severely affected.<sup>7</sup> Approximately half of patients who undergo below-the-knee (BTK) amputations are able to regain household mobility, and less than a quarter regain mobility outside of the home.<sup>8</sup> Beyond the loss of functional ability, patients who undergo amputation are at an increased risk of mortality, with rates reaching approximately 25% of patients at 1 month, 50% at 1 year, and 75% at 5 years.<sup>9</sup> Considering the detrimental outcomes of amputation, limb salvage remains the primary goal of contemporary CLI treatment.<sup>10</sup>

The LimFlow percutaneous deep vein arterialization (pDVA) approach to treating CLI is an evolution of the



**FIGURE 1.** Example of baseline wound and angiographic imaging with limited arterial distal flow.

concept of venous arterialization, a procedure that has been performed surgically for many years, with the first clinical surgical cases reported in the early twentieth century.<sup>11,12</sup> Multiple small clinical trials on a surgical approach have been published, and a recent meta-analysis article summarized this work. Despite the promising initial findings that limb salvage can be obtained with utilization of venous arterialization, the technique has not been widely adopted due to the technical challenges and potential morbidity of the surgical operation.<sup>13</sup>

Clinical studies utilizing LimFlow pDVA for intervention in no-option CLI patients were first performed in Singapore and Europe, with CE mark approval granted in October 2016. Early experiences resulted in promising outcomes in high-risk no-option CLI patients with a 6-month limb salvage rate of 86%<sup>3</sup> and clinical improvement in 60%.<sup>14</sup> In 2017, a pilot study instituted as part of the Food and Drug Administration's early feasibility study program was launched in the United States. Presented here is the first experience of the LimFlow system in the United States.

## Methods

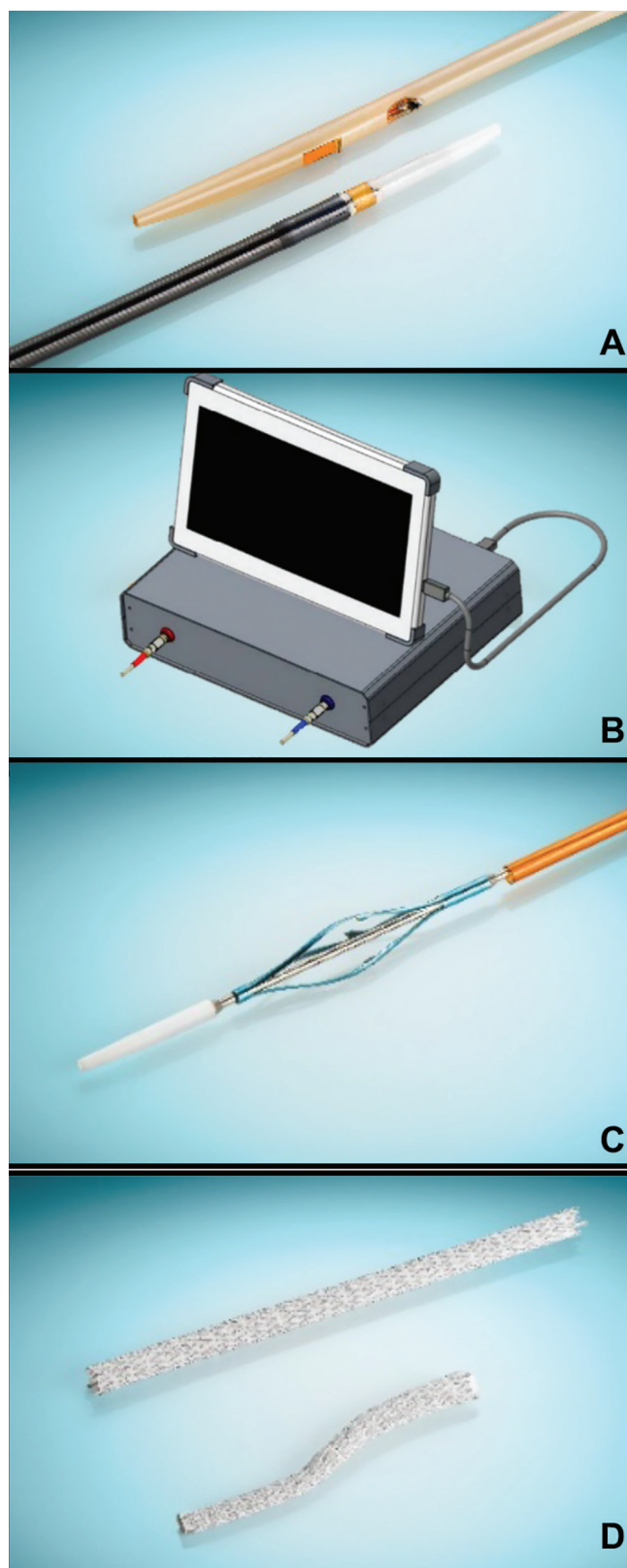
**Design and patient population.** The PROMISE I trial is a single-arm, multicenter, pilot study conducted to investigate the feasibility, safety, and effectiveness of the LimFlow stent-graft system. Ten patients with no-option CLI were enrolled at three hospitals across the United States (Metro Heath, Grand Rapids, Michigan; Palmetto Health, Columbia, South Carolina; and Kaiser Permanente, Honolulu, Hawaii) between

July 2017 and January 2018, with preliminary results through 6 months reported here (follow-up is ongoing through 24 months). Trial enrollment has since been expanded to 35 subjects with additional United States medical centers included.

Eligible patients were  $\geq 21$  years old with Rutherford classification (RC) 5 or 6 who were determined to have no feasible option for conventional revascularization. No-option status was defined as the lack of ability to perform conventional distal surgical bypass or endovascular therapy for limb salvage due to the absence of a usable pedal artery target or suitable vein conduit. In addition to the strict no-option definition, key exclusion criteria included immunodeficiency disorder, thrombophlebitis, deep vein thrombus or coagulation disorder, active infection that would preclude graft insertion, elevated creatinine, and end-stage renal disease.

The study was conducted in accordance with the International Conference of Harmonization Guidelines for Good Clinical Practice and prospectively registered at ClinicalTrials.gov (NCT03124875). Institutional review board approval was received for each study site. Following signed patient informed consent, all patients were confirmed as no-option by an Independent Safety Committee (ISC) before enrollment in the study. The ISC also participated in ongoing review of study safety data to ensure the rights and welfare of study patients were protected.

**Study device and procedure.** No-option CLI patients who underwent the study intervention presented with both non-healing wounds and poor arterial run-off (Figure 1). The pDVA treatment approach was utilized to create an



**FIGURE 2.** Components of the LimFlow stent-graft system. [A] Arterial and venous catheters. [B] Ultrasound console. [C] Forward-push valvulotome. [D] Electrospun polytetrafluoroethylene stent grafts.

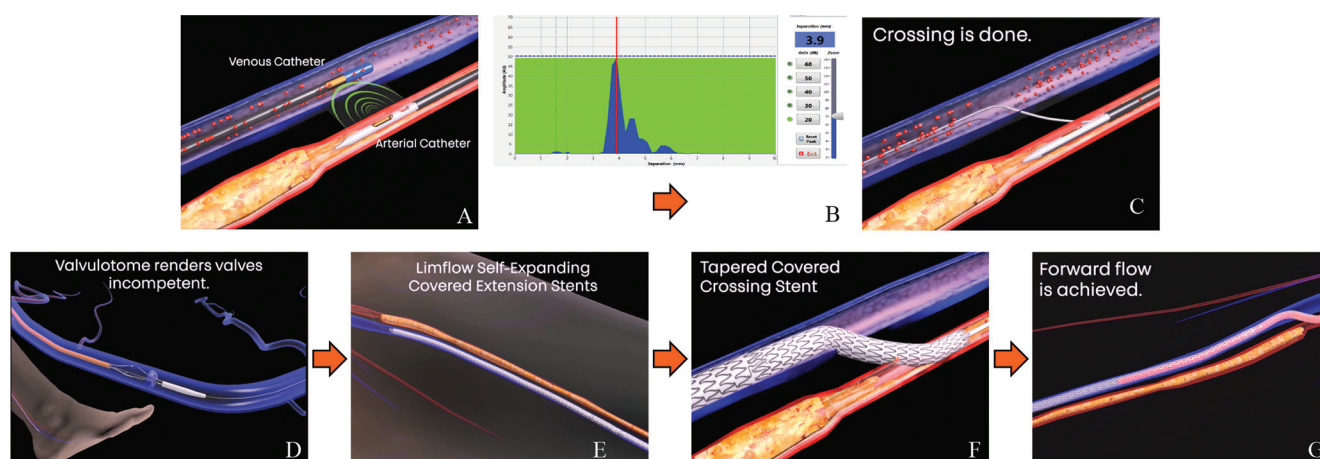
arteriovenous fistula and generate an alternative conduit for blood flow to the foot through use of a tibial vein. The system consists of arterial and venous catheters, an ultrasound console, a forward-push valvulotome, and electrospun polytetrafluoroethylene (PTFE) stent-grafts (Figure 2).

During the procedure, an antegrade femoral arterial approach is utilized to insert a 7 Fr sheath and a retrograde tibial venous approach is utilized to insert a 5 Fr sheath. Both access points are placed under ultrasound guidance and used as the working channels for the procedure. The arteriovenous crossover point is located proximal to the total occlusion of the artery and is determined by angiography with consideration of the vascular anatomy. The arterial and venous catheters are then inserted from opposing directions and aligned utilizing ultrasound guidance from the console (Figure 3A). The arterial catheter has a small, single-directed ultrasonic transmitter as its tip and the venous catheter features a 360° ultrasonic sensor, allowing each to detect the other catheter in the neighboring vein/artery. The catheters are connected to an ultrasound console that applies short electrical pulses to the arterial transmit catheter. The signal received by the venous catheter is displayed on the console as a waveform, permitting orientation of the two catheters (Figure 3B). Once complete orientation is achieved, the crossing needle is extended from the arterial catheter into the target vein and a crossing wire is advanced through a support catheter down to the pedal vein (Figure 3C). The crossover point is then ballooned and serves as the working channel for the remainder of the procedure.

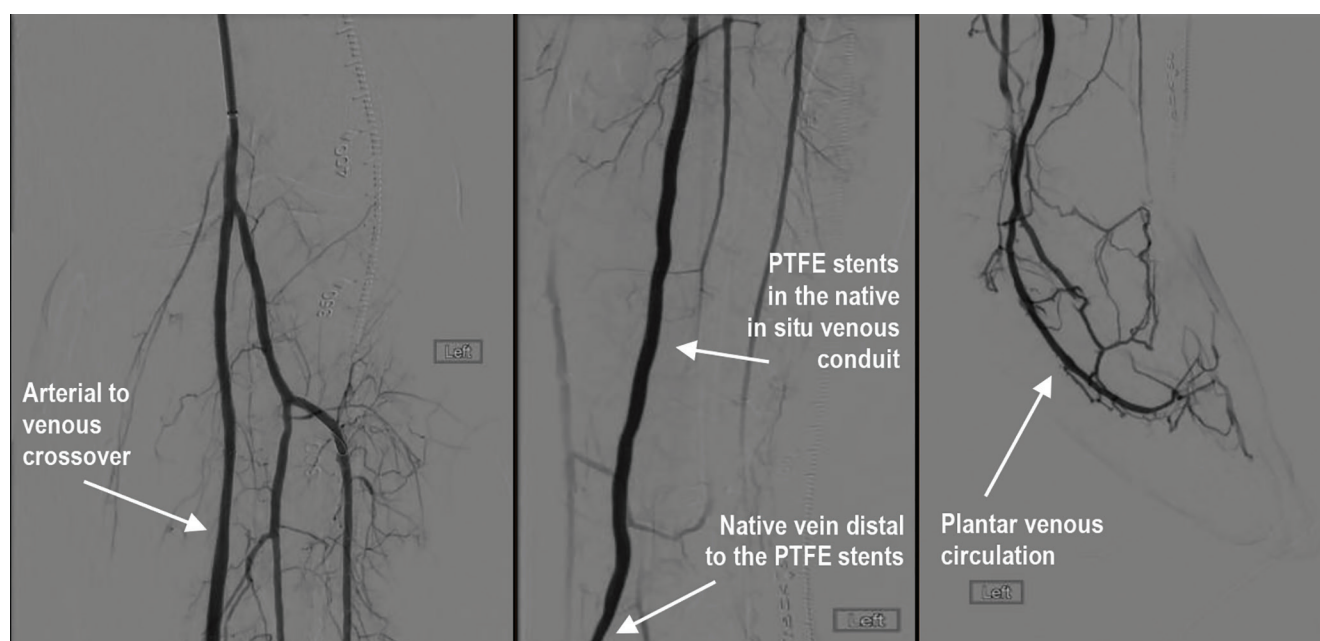
After a wire has been advanced from the artery to the vein, it is advanced into the lateral plantar vein. The wire is passed through the venous arch through which outflow will be established once the revascularization is completed. Wire passage through the pedal venous arch creates the support that provides a stable and rigid rail for the delivery of the forward-push valvulotome and the stent-grafts. The valvulotome is then inserted over the wire and is utilized to render the venous valves incompetent in order to allow the retrograde flow of blood into the venous system (Figure 3D). Finally, the length of the vein from above the ankle to the crossover point is lined with electrospun PTFE-covered stents (Figure 3E) and the crossover point is covered with a reverse-conical PTFE stent-graft (Figure 3F), completing the conduit for blood flow (Figure 3G). Figure 4 demonstrates a representative angiographic result.

**Study endpoints and follow-up.** Clinical evaluations were performed at 1, 3, and 6 months following the procedure. Patient follow-up is currently ongoing, with postprocedure evaluations at 9, 12, and 24 months. Routine surveillance of the wound and index limb is performed during each follow-up visit, in accordance with the 2006 American College of Cardiology/American Heart Association peripheral disease guidelines. Examinations included assessments of pulse, pain, R.C, oxygenation, wound-healing status, and





**FIGURE 3.** Steps of LimFlow percutaneous deep vein arterialization. [A] Arterial and venous catheters aligned. [B] Signal received by the venous catheter displayed as a waveform, permitting orientation. [C] Crossing needle extension from arterial catheter into target vein and crossing wire advancement. [D] Valvulotome insertion over crossing wire and utilization to render venous valves incompetent. [E] Length of vein from above the ankle to crossover point lined with polytetrafluoroethylene (PTFE)-covered stents. [F] Crossover point lined with conical PTFE-covered crossing stent. [G] Forward flow of blood to foot achieved.

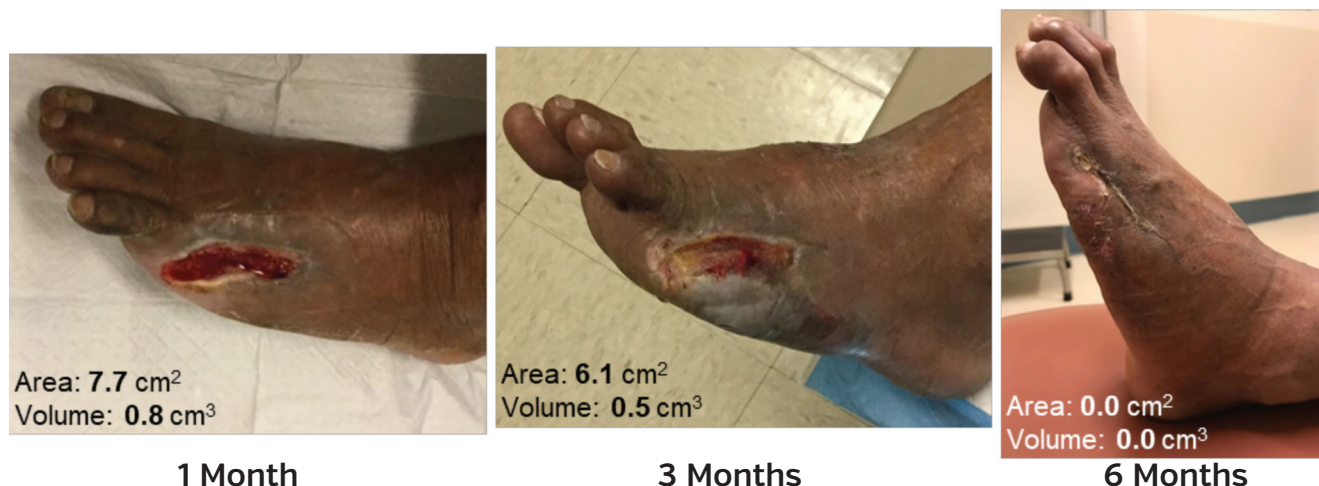

**FIGURE 4.** Angiographic imaging of lower-extremity arterial flow post percutaneous deep vein arterialization.

any procedures or complications related to the index limb. Patients were assessed for wound healing using quantitative wound measurement and qualitative tissue description.

The *primary endpoint* was amputation-free survival at 30 days, defined as index limb salvage (freedom from above-ankle amputation) and survival (freedom from all-cause mortality). *Secondary endpoints* included amputation-free survival at 6 months, primary patency at 30 days and 6 months (defined as absence of occlusion of the stent-graft without

prior clinically-driven major reintervention of the graft), wound healing at 3 and 6 months (defined as complete index wound healing), and deterioration in renal function at 6 months (25% increase in serum creatinine after using iodine contrast agent without another clear cause for kidney injury). *Technical success* was also evaluated, and was defined as completion of the endovascular procedure and immediate morphological success with successful placement of the arterial and venous catheters and stent-grafts.



**FIGURE 5.** Example of wound healing through 6 months post intervention.

**Statistical analysis.** This pilot study enrolled a small number of patients to evaluate the device design concept with respect to initial clinical safety and device functionality; as such, the statistics are descriptive in nature. Measures of safety and efficacy were assessed through hospital discharge, at  $30 \pm 7$  days, and at 3 and 6 months ( $\pm 2$  weeks) post procedure. Patient demographics, baseline characteristics, and medical history are summarized descriptively. Frequencies and proportions are reported for categorical variables.

## Results

Ten no-option CLI patients comprised the patient population; a total of 7 patients (70%) were male and 3 patients (30%) were female, with an average age of  $67 \pm 11$  years. Five patients (50%) were African-American. Comorbidity and risk factors included diabetes (80%), hypertension (70%), heart failure (New York Heart Association class I, 60%), history of stroke (20%), history of cardiac event (myocardial infarction or coronary artery disease, 30%), and history of smoking (60%). Average glomerular filtration rate (GFR) was  $62 \pm 23$  mL/min/1.73 m<sup>2</sup> and average serum creatinine level was  $1.3 \pm 0.4$   $\mu$ mol/L. Six patients (60%) were RC 5 and 4 patients (40%) were RC 6. Eight patients (80%) were categorized as stage 4 (high risk for amputation) according to the Society for Vascular Surgery (SVS) wound, ischemia, and foot infection (WIFI) index (Table 1).

The posterior tibial artery and vein were the most commonly used target vessels (60%), followed by the anterior tibial (30%), and the peroneal (10%). The majority (90%) of procedures were performed under general anesthesia. Most patients (80%) required arterial preparation (including balloon angioplasty and stenting to treat inflow disease) prior to the use of the LimFlow system, and 30% required venous preparation (including balloon angioplasty to treat venospasm).

Among the 10 patients enrolled in this pilot study, a 100% technical success rate was observed in the revascularization of the foot and all maintained amputation-free survival through 6 months. No patients experienced a deterioration of renal function. Postprocedure adverse events included access-site pain and bleeding, edema, and pain in the target limb. There were no procedural complications or post-procedure severe adverse events reported. The only severe adverse events reported through the 6-month follow-up were for reintervention to restore patency. One patient refused in-person follow-up at 6 months, but was followed via phone interview for the primary endpoint.

At 1-month follow-up, primary patency was maintained in 90% of patients; at 6 months, primary patency was 40%. Thirty percent of patients underwent reintervention within the 6-month timeframe, with 1 patient undergoing 2 reinterventions. Two of the 3 patients had a pulse present by Doppler distal to their occluded stent at the time of reintervention. At the 6-month follow-up, only 1 patient had an absent pulse distal to the stent-graft (assessed by duplex ultrasound). Thirty percent of patients required transmetatarsal amputation (1 patient at 1 month post intervention, 2 patients at 3 months post intervention) and 20% underwent digit amputation (1 patient at 3 months post intervention, 1 patient at 5 months post intervention).

At 6 months, all patients experienced progressive wound healing, with complete wound healing occurring in 30% of patients. Half of the patients had 84%–93% wound healing by 6 months and 2 patients were noted with approximately 60% overall healing. Throughout the follow-up, healthy granulation tissue, an indicator of healing,<sup>15</sup> was found in the wounds of all patients. Figure 5 shows an example of target-wound healing. Noted acceleration in healing occurred after the postprocedure 1-month follow-up, which was likely a result of maturation of the arterialization.

**Table 1. Baseline patient characteristics and outcomes.**

Variable	[n = 10]
<b>Demographics</b>	
Age [years]	67 ± 11
Gender, male	7 [70%]
Ethnicity, African American	5 [50%]
<b>SVS Wifi high-risk staging</b>	
High risk [clinical stage 4]	8 [80%]
Moderate risk [clinical stage 3]	1 [10%]
Low risk [clinical stage 2]	1 [10%]
<b>Comorbidities</b>	
Diabetes	8 [80%]
Smoking history	6 [60%]
Body mass index [kg/m <sup>2</sup> ]	26 ± 4
Cardiac event history	3 [30%]
Hypertension	7 [70%]
Stroke history	2 [20%]
Dialysis	0 [0%]
<b>Kidney function</b>	
eGFR [mL/min/1.73 m <sup>2</sup> ]	62 ± 23
Serum creatinine [μmol/L]	1.3 ± 0.4
<b>Outcomes</b>	
Amputation-free survival at 1 & 6 months	10 [100%]
Technical success rate	10 [100%]
Primary patency at 1 month	9 [90%]
Primary patency at 6 months	4 [40%]
Complete wound healing at 6 months	3 [30%]
Reintervention required	3 [30%]
Transmetatarsal amputation required	3 [30%]
Minor amputation [toe] required	2 [20%]
Data provided as mean ± standard deviation or number [%]. eGFR = estimated glomerular filtration rate; SVS Wifi = Society for Vascular Surgery wound, ischemia, and foot infection score.	

## Discussion

Since the initial findings reported by Halstead and Vaughan regarding use of venous arterialization for limb salvage,<sup>12</sup> several mechanisms have been noted to support utilization of this technique. Use of the venous bed as a conduit for perfusion has been found to successfully increase flow through existing collateral vessels, improve tissue perfusion and nutrition in the capillary beds, and stimulate angiogenesis.<sup>13,16,17</sup> A meta-analysis of 15 studies that included 768 CLI patients who had venous arterialization performed for lower-limb salvage found that the pooled limb-salvage rate at 12 months was 75%. These findings were promising for patients presenting with no arterial reconstruction options. Within the 15 studies, venous arterialization was performed surgically.<sup>13</sup> Kum et al

reported the initial clinical findings of pDVA performed on 7 no-option CLI patients in Singapore. Technical success and primary safety endpoints were achieved in 100% of patients, with no above-ankle amputations, deaths, or major reinterventions required at 30 days. Complete wound healing was noted in 57% of patients at 6 months and 71% of patients at 1 year. Within this small cohort of patients, pDVA appeared to be a safe and feasible approach for limb-salvage treatment.<sup>3</sup> The evolution from surgical to percutaneous venous arterialization offers the benefit of lower procedural risks and eliminates the need to create a surgical wound in the ankle or foot of a critically ischemic limb.<sup>13</sup> In addition, the development of contemporary devices for pDVA enhances the potential for clinical success. Ultrasound-guided dual catheters offer a reliable approach for arteriovenous fistula creation, the reverse valvulotome allows for a less traumatic approach than barotrauma to render the valves incompetent, and extension stent-grafts create a large-caliber shunt analogous to a surgical bypass.<sup>14</sup>

The interim findings reported here represent the first 10 patients to be treated with the LimFlow pDVA system in the United States. At the time of screening for the feasibility trial, all patients were evaluated for surgical or endovascular intervention by the treating investigator and the Independent Safety Committee and were deemed to have no feasible options for revascularization. Treatment of the patients' presenting wounds with a minor (toe or transmetatarsal) amputation was not a viable approach in these ischemic limbs without a corresponding intervention to improve wound perfusion. Without the pDVA endovascular procedure, conservative wound treatment, leading most likely to major amputation, was the only medical therapy available to these no-option patients. All patients treated with the LimFlow system experienced successful revascularization of the foot and were alive and amputation free at the 6-month endpoint. Those patients who did not maintain patency and/or required revascularization continued to heal and met the primary endpoint, indicating that occlusion that occurred once the healing process had initiated did not appear to translate to worsening outcomes. It is feasible that the increase in oxygenated flow allowed for collateral growth, but there is additional work to be done to determine the mechanism behind this observation.

The primary goals of CLI treatment are preservation of a functional limb with minimization of tissue loss and promotion of wound healing.<sup>18</sup> Utilization of pDVA endovascular revascularization resulted in a 100% 6-month limb salvage and a progression toward complete wound healing for all patients. Patients diagnosed with CLI face a substantial clinical burden, with 4-year survival rates of 46%.<sup>19</sup> The rates of morbidity and mortality remain substantially higher for patients whose clinical course results in a major amputation (mortality of 13.5% vs 6.9% at 1 month, 48.3% vs 24.2% at 1 year, and 70.9% vs 43.2% at 3 years), and the continued



reduction of these amputations could predict continued reduction in overall patient mortality.<sup>20</sup> Although QoL measurements were not included in this pilot study, one can extrapolate that the promising outcome of limb salvage with wound-healing progression would also result in a rise in the patient's functional and overall QoL. Thus, pDVA endovascular revascularization with the LimFlow system appears to offer a promising treatment modality for no-option CLI patients who currently face a poor prognosis.

**Study limitations.** The initial analysis of the PROMISE I trial was limited to a small sample size with enrollment performed at three medical centers. Despite the small number of medical centers included, the investigators had varied specialties, including endovascular interventionists and vascular surgeons. The current data only extend to 6 months. Patient enrollment is ongoing, with inclusion of additional medical centers, and long-term follow-up will continue through 2 years.

## Conclusion

The LimFlow stent-graft system is a novel treatment modality for no-option CLI patients. The initial feasibility trial outcomes revealed complete avoidance of major amputation at 6 months with progressive wound healing. The treatment was performed safely, with no instances of procedural complication or decreased renal function in patients. These are promising findings in a subset of patients for whom amputation would otherwise be considered inevitable. Additional study through ongoing enrollment and follow-up in the early feasibility trial, as well as a larger-scale trial, is warranted. In this initial cohort, the LimFlow treatment was technically feasible, safe, and effective for the revascularization of no-option patients suffering from severe CLI.

## References

- Conte MS. Bypass versus angioplasty in severe ischaemia of the leg [BASIL] and the [hoped for] dawn of evidence-based treatment for advanced limb ischemia. *J Vasc Surg.* 2010;51:69S-75S.
- Mustapha J, Finton S, Diaz-Sandoval L. Percutaneous transluminal angioplasty in patients with infrapopliteal arterial disease systematic review and meta-analysis. *J Vasc Surg.* 2016;64:1170-1171.
- Kum S, Tan YK, Schreve MA, et al. Midterm outcomes from a pilot study of percutaneous deep vein arterialization for the treatment of no-option critical limb ischemia. *J Endovasc Ther.* 2017;24:619-626.
- Slovut DP, Sullivan TM. Critical limb ischemia: medical and surgical management. *Vasc Med.* 2008;13:281-291.
- Faglia E, Clerici G, Clerissi J, et al. Long-term prognosis of diabetic patients with critical limb ischemia: a population-based cohort study. *Diabetes Care.* 2009;32:822-827.
- Lichtenberg M, Schreve MA, Ferraresi R, et al. Surgical and endovascular venous arterialization for treatment of critical limb ischaemia. *VASA.* 2018;47:17-22.
- Sprengers RW, Teraa M, Moll FL, Wit GAD, Graaf YVD, Verhaar MC. Quality of life in patients with no-option critical limb ischemia underlines the need for new effective treatment. *J Vasc Surg.* 2010;52:843-849, 849.e1.
- Davies B, Datta D. Mobility outcome following unilateral lower limb amputation. *Prosthet Orthot Int.* 2003;27:186-190.
- Fortington LV, Dijkstra PU, Geertzen JHB. Determinants of discharge to long-term care after a lower limb amputation. *J Am Geriatr Soc.* 2013;61:298-299.
- Sprengers RW, Lips DJ, Bemelman M, Verhaar MC, Moll FL. Lower leg amputation due to critical limb ischaemia: morbidity, mortality and rehabilitation potential. *Ned Tijdschr Geneesk.* 2007;151:2185.e91.
- Francois-Franck M. Note à propos de la communication de M Raimond Petit sur la suture artério-veineuse. *Comptes Rendus Acad Sci.* 1896;48:150.
- Halstead AE, Vaughan RT. Arteriovenous anastomosis in the treatment of gangrene of the extremities. *Surg Gynecol Obstet.* 1912;14:1.
- Schreve M, Vos C, Vahl A, et al. Venous arterialisation for salvage of critically ischaemic limbs: a systematic review and meta-analysis. *Eur J Vasc Endovasc Surg.* 2017;53:387-402.
- Giudice CD, Heuvel DVD, Wille J, et al. Percutaneous deep venous arterialization for severe critical limb ischemia in patients with no option of revascularization: early experience from two European centers. *Cardiovasc Intervent Radiol.* 2018;41:1474-1480.
- Grey JE, Enoch S, Harding KG. Wound assessment. *BMJ.* 2006;332:285-288.
- Baffour R, Danylewski R, Burdon T, et al. An angiographic study of ischemia as a determinant of neovascularization in arteriovenous reversal. *Surg Gynecol Obstet.* 1998;166:28-32.
- Jacobs MJ, Reul GJ, Gregoric ID, et al. Creation of a distal arteriovenous fistula improves microcirculatory hemodynamics of prosthetic graft bypass in secondary limb salvage procedures. *J Vasc Surg.* 1993;18:1-9.
- Gerhard-Herman MD, Gornik HL, Barrett C, et al. 2016 AHA/ACC guideline on the management of patients with lower extremity peripheral artery disease: executive summary: a report of the American College of Cardiology/American Heart Association task force on clinical practice guidelines. *J Am Coll Cardiol.* 2017;69:1465-1508.
- Mustapha JA, Katzen BT, Neville RF, et al. Determinants of long-term outcomes and costs in the management of critical limb ischemia: a population based cohort study. *J Am Heart Assoc.* 2018;7:e009724.
- Jones S, Swaminathan A, Patel M, Vemulapalli S. Lower extremity amputation in peripheral artery disease: improving patient outcomes. *Vasc Health Risk Manag.* 2014;10:417-424.

From the <sup>1</sup>Advanced Cardiac and Vascular Amputation Prevention Centers, Grand Rapids, Michigan; <sup>2</sup>Palmetto Health USC Medical Group, Columbia, South Carolina; and <sup>3</sup>Kaiser Foundation Hospital and Kaiser Permanente Medical Group, Honolulu, Hawaii.

Funding: The Promise I trial was sponsored by LimFlow, Inc.

Disclosure: The authors have completed and returned the ICMJE Form for Disclosure of Potential Conflicts of Interest. Dr Mustapha reports consultant income from LimFlow. Dr Schneider reports consultant income from Silk Road, Surmodics, Profusa, CSI, Cardinal Health; scientific advisory board for Abbott, Medtronic, and Boston Scientific. The remaining authors report no conflicts of interest regarding the content herein.

The authors report that patient consent was provided for publication of the images used herein.

Manuscript submitted December 18, 2018, provisional acceptance given December 21, 2018, final version accepted January 4, 2018.

Address for correspondence: Jihad A. Mustapha, MD, Advanced Cardiac and Vascular Amputation Prevention Centers, 1525 E. Beltline Ave. NE, Suite 101, Grand Rapids, MI 49525. Email: jmustapha@acvcenters.com